

Use of CellerateRX Surgical, Hydrolyzed Collagen Powder on Non-Healing Left Clavicle

Dr. Dinaker Golla

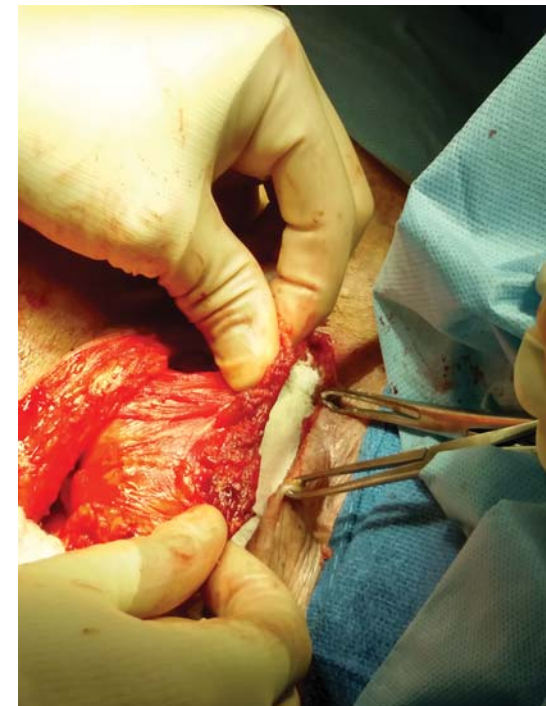
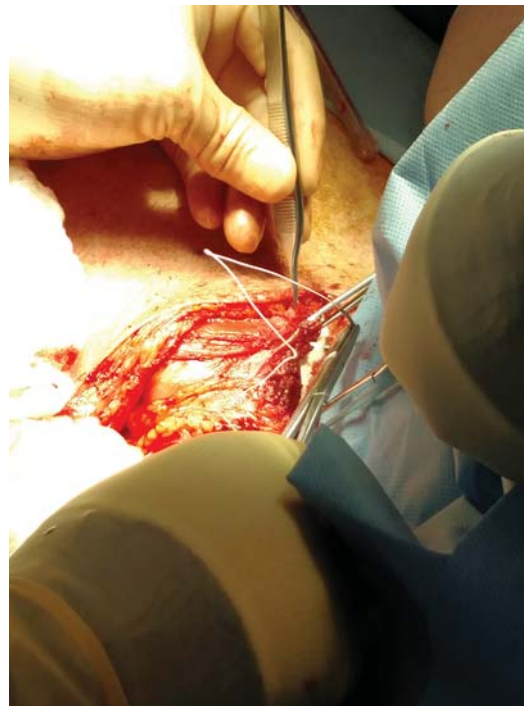
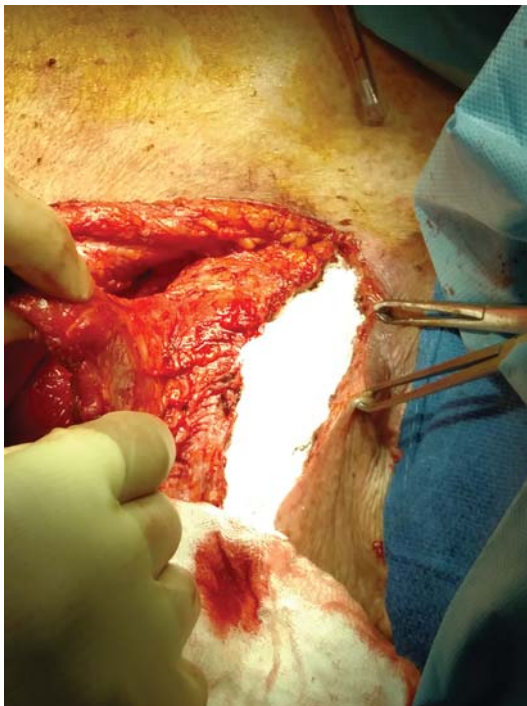
Patient History

80-year-old male with a PMHx of frequent falls, HTN, DVT, PVD. We have been following patient for a non-healing left clavicle wound since April 2015. He sustained the wound s/p fall that left a hematoma that was subsequently aspirated x2. Previously being treated with Dakins soaked packings BID.

Treatment

Underwent a left clavicle debridement with pectoral flap with use a cellerate by Dr. Golla on 5/12/2015. Four (4) grams of CellerateRx Surgical powder was placed into the wound as per product instructions and the wound closed.

BELOW: The wound during surgery.

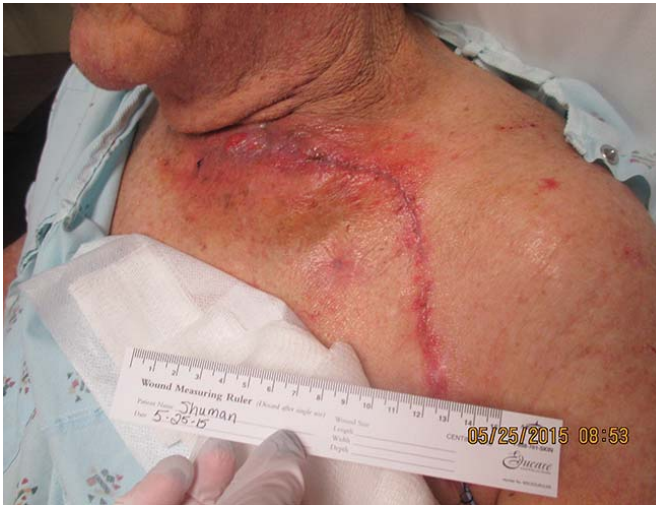
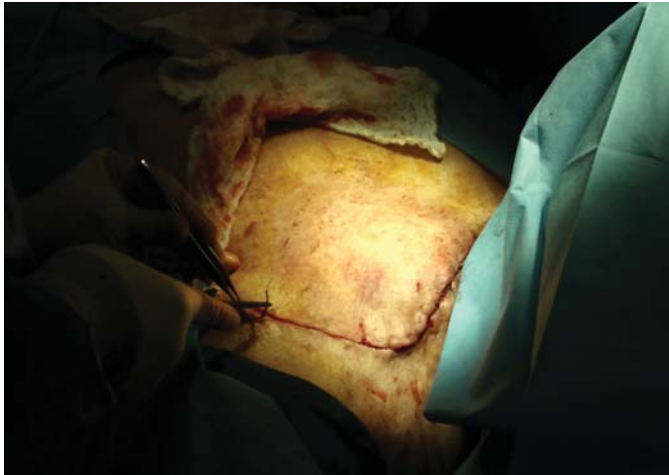
Designed by Nature Activated By Science

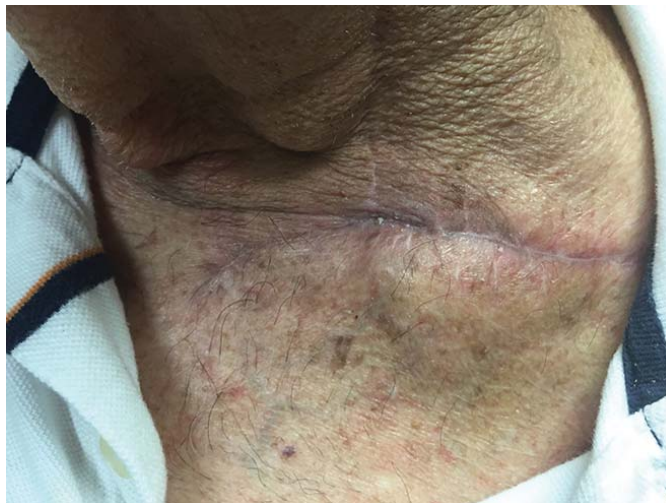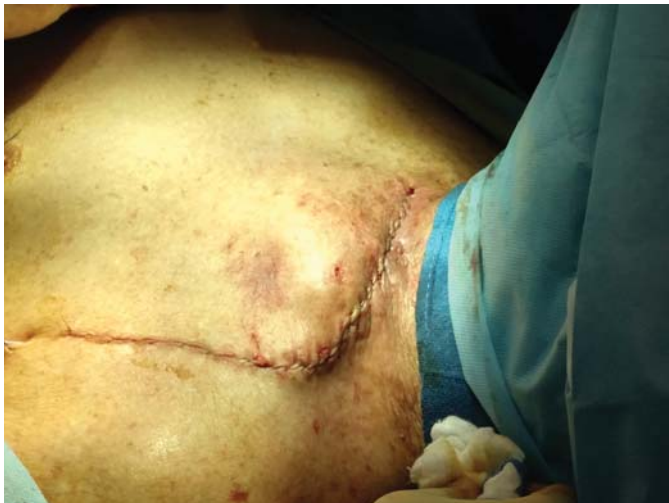Results:

The patient fully healed with no infection and no drainage.

Below: The wound during surgery on 5/12/2015.



Left: The wound after two (2) weeks.



Left: The wound on 06/22/15